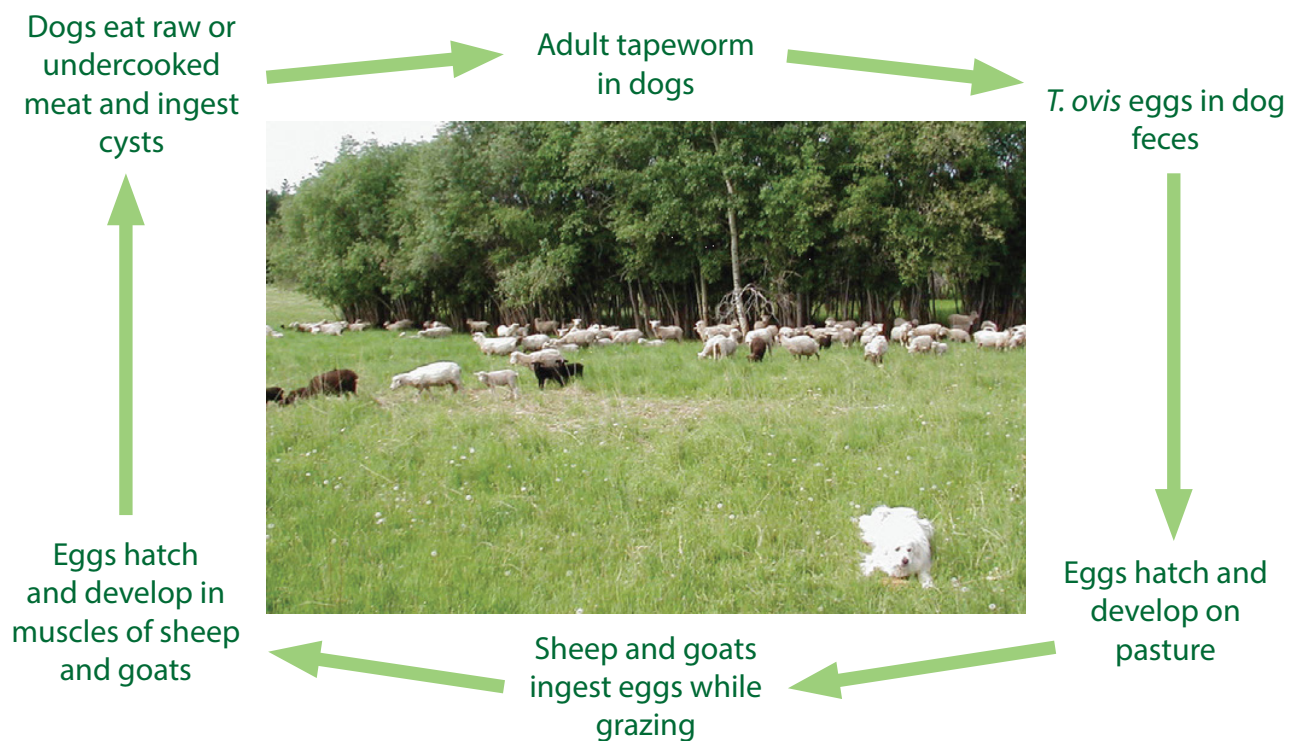


# Cysticercus ovis

## What do you need to know when slaughtering sheep and goats?

### About *Cysticercus ovis*

*Taenia ovis* is a tapeworm found in domestic and wild canines. Eggs are shed in their feces and contaminate the environment. As indicated in the diagram, sheep and goats can ingest the eggs while grazing or eating contaminated feed. Larvae hatch from these eggs and migrate into the muscles and form cysts. These parasites are then referred to as *Cysticercus ovis* (*C. ovis*). Canines ingest these cysts when consuming raw or undercooked sheep and goat meat and continue the lifecycle. *C. ovis* does not affect humans and, unlike *Cysticercus bovis* in cattle, is not reportable to the Canadian Food Inspection Agency (CFIA). Condemnation, however, is necessary in certain circumstances.



*Dog and sheep photo courtesy of Alberta Lamb Producers*

### *C. ovis* occur in Saskatchewan

The current level of *C. ovis* infection in Saskatchewan is not considered high, but careful monitoring at the abattoir level is key to ensure that any cases of *C. ovis* are detected and reported to the Canadian Sheep Federation (CSF). Through vigilant observation, abattoirs will play a key role in minimizing the cost of this disease on the industry.

### Appearance of cysts

Cysts are approximately 5 mm x 9 mm in size. In the initial stages, cysts appear fluid-filled. Later on, they are described as hard and caseous (cheese-like) in appearance.

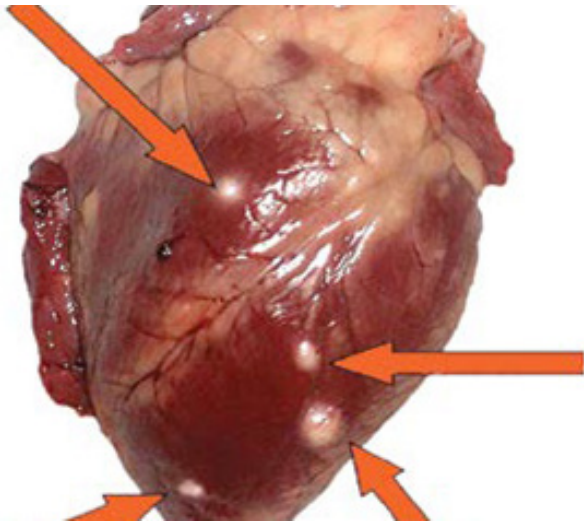


Photo credit: T. Hagedorn

### Location of cysts

Cysts are located in different muscle groups. In sheep and goats, these are most often found in the masseters, tongue, heart, esophagus, and diaphragm.

### How to handle carcasses

If cysts are discovered during slaughter, the decision for condemnation or carcass trimming depends on the level of infection. If mildly affected, the carcass can be trimmed and pass for human consumption. If heavily affected, the carcass should be condemned for quality reasons. This does not affect human health.

### “Heavily” affected carcasses

A carcass is considered heavily affected if cysts are found in at least two sites during inspection (such as the tongue and heart) and at least two sites on the rounds and forelimbs when exposed by incision.

### What to do if cysts are detected

The CSF works to educate producers and value chain members about the impact of *C. ovis* condemnations to producers, feedlots, processors and the industry. If cysts are detected during inspection, cases should be reported to the CSF, who will provide education on management and prevention to stakeholders.

If cysts are detected, report them to the CSF at 1-888-684-7739 or [info@cansheep.ca](mailto:info@cansheep.ca).

### How infection can be prevented

- Deworm all dogs in contact with sheep and goats with appropriate treatment;
- If cysts are discovered, dogs should be dewormed monthly;
- Do not feed raw or undercooked sheep and goat meat to dogs; and
- Appropriately dispose of dead stock to decrease scavenging.